

*Functional Aesthetics in Implantology and
Reconstructive Dentistry: Analysis and
Transfer of Referenced Individual Patient
Information With the PlaneSystem®*

Siegfried Marquardt & Udo Plaster

Current Oral Health Reports

e-ISSN 2196-3002

Curr Oral Health Rep
DOI 10.1007/s40496-019-00246-1



Your article is protected by copyright and all rights are held exclusively by Springer Nature Switzerland AG. This e-offprint is for personal use only and shall not be self-archived in electronic repositories. If you wish to self-archive your article, please use the accepted manuscript version for posting on your own website. You may further deposit the accepted manuscript version in any repository, provided it is only made publicly available 12 months after official publication or later and provided acknowledgement is given to the original source of publication and a link is inserted to the published article on Springer's website. The link must be accompanied by the following text: "The final publication is available at link.springer.com".



Functional Aesthetics in Implantology and Reconstructive Dentistry: Analysis and Transfer of Referenced Individual Patient Information With the PlaneSystem®

Siegfried Marquardt¹ · Udo Plaster²

© Springer Nature Switzerland AG 2019

Abstract

Purpose of Review The goal of every dental treatment should be a sustainable and functional care which is adapted to the individual movement patterns. In this context, a structured and anatomically accurate functional analysis can contribute to the correct muscular and skeletal adjustment of patients in order to develop the correct treatment strategy, which then guarantees a permanently stable reconstruction. The individual and whole-body analysis as well as the dental history of the patient and the correct transfer into the articulator play an important role. How accurately can the dental technician judge the actual situation of the patient? How realistic are planes, chewing patterns, jaw joint movements and closing angles represented in the articulator compared to the oral situation? Innovative aspects such as the reference to the natural head position (NHP), the exact determination of the anatomical centre and the correct three-dimensional transfer into the articulator are decisive factors which influence the success of the treatment.

Recent Findings This article focuses on the realistic, correctly positioned transfer of the casts and other anatomical parameters into the analogue or virtual articulator. The development of the function-analytical method is presented using the PlaneSystem®. The detection of patient-specific details using the analogue method (e.g. head posture, facial proportions, physiognomic landmark, cast analysis, cast orientation, movement recording, joint mechanics, lower jaw position in physiological, unmanipulated centric) as well as the digital procedure (e.g. facial scan, three-dimensional analysis, photo documentation) and their transfer into the articulator form the basis. The occlusal plane and asymmetries are measured individually for each patient and transferred into the articulator in the same way as the vertical dimension of the occlusion (VDO) and the alignment of the lower jaw. All collected information can finally be integrated into a digital workflow so that reference can be made to purely virtual solutions.

Summary In the following, the necessity out of which the systematics developed as well as the individual development stages are described. Furthermore, the potential is illustrated in that the use of this method offers to the prosthetic working team.

Keywords Implant prosthetics · All-ceramics · Labial veneering · PlaneSystem® · Anatomical transfer · NHP (natural head position)

This article is part of the Topical Collection on *Modern Production Laboratory Advances in Dental Technology*

✉ Siegfried Marquardt
info@dr-marquardt.de

Udo Plaster
info@plasterdental.de

¹ Zahngesundheit am Tegernsee, Adelhofstrasse 1,
83684 Tegernsee, Germany

² Plaster Dental-Technik, Emilienstrasse 1,
90489 Nuremberg, Germany

Introduction

Increasingly, harder materials such as zirconium dioxide but also inflexible, osseointegrated implants characterise modern reconstructive dentistry. Functional and biomechanical aspects play a more important role than ever.

The psychosocial stress of our society moves increasingly to the centre of the attention, and muscular tensions, teeth grinding and bruxism cannot be stopped by hard materials and implants. Therefore, a functional analysis is crucial for the success of the treatment.

Phenomena such as chipping, implant fractures and the resulting jaw joint problems are often caused by functional misjudgements and misalignments.

Each person brings his or her individual situation to the dental practice with specific requirements. When viewed in their entirety, these individual circumstances indicate—like a compass—the solution to be adopted for the treatment. A solid collection of information about the anatomical characteristics of the patient, a detailed analysis and diagnosis of the dental history as well as the current situation and the well-founded use of digital dental technologies are important forerunners/precursors.

Thanks to digital technology, clinical information taken from the patient's mouth can be synchronised 1:1 with the dental workplace.

With the PlaneSystem®, information can be transferred from the analogue to the digital world—and vice versa—without any loss of information. This allows to record the individual patient situation as a whole, to reference it on the basis of defined values and to reproduce it exactly at any time. This reproducibility offers a high degree of security, especially for complex therapies.

The PlaneSystem® is a transmission method which respects and analyses the patient in his entirety as a human being with its skeletal and physiological patterns. Irrespective of whether the purely digital or conventional method is chosen for the fabrication of a dental restoration, the exact and individual recording of the patient's anatomy with the PlaneSystem® paves the way for the comprehensive safeguarding of the patient's health.

The following shows the prosthetic rehabilitation of a patient who was not only provided with a very aesthetic restoration made of monolithic ceramics but who was also liberated from many years of physical pains.

Case Report

Two reasons were decisive for the patient to present herself at the dental practice:

- She did not like the aesthetic situation as a whole, and in recent years, she increasingly noticed the asymmetry of her smile, which seemed unattractive to her.
- For years, the patient was under medical and physiotherapeutic care due to chronic neck and back pain, unclear headaches and selective states of exhaustion. She herself, but also the therapists, recently suspected a connection with the masticatory organ, as the numerous treatments did not lead to any improvement.

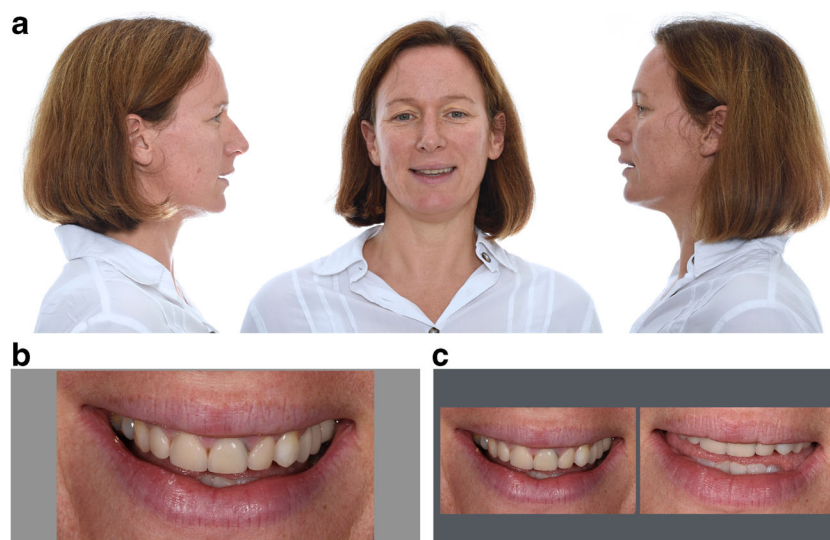The assumption that a dysfunctional denture (Fig. 1a–c) could be the reason for the pains was obvious after a short anamnesis and analysis.

According to Hergenroether [1], the body compensates deviations in the orofacial system with incorrect posture. In the case of *descending chains*, these compensatory incorrect loadings have an effect on the entire skeletal and muscular systems from head to toe due to an incorrect masticatory pattern (e.g. due to unadjusted dentures).

Therefore, in such cases, a close coordination between orthopaedist, physiotherapist or osteopath, dentist and laboratory is absolutely necessary. All participants need the same information status and are requested to make a comprehensive diagnosis and to coordinate this with each other.

The diagnosis consists first of all of recording the dental anamnesis and history. The patient had an orthodontic treatment as a teenager, and in this context, tooth 14 was removed early. Teeth have been removed from the patient's lower jaw

Fig. 1 a–c The patient suffers from whole-body discomfort. The physiotherapist suspects that the reason for this are dysfunctional dentures. The diagnosis begins



in 2012/2013, whereupon the neck problems, which had already existed for years, intensified once again.

A radiological diagnosis performed by an orthopantomogram complements and confirms the clinical picture (Fig. 2a,b).

The existing denture and various composite fillings in the upper and lower jaws were mostly insufficient and aesthetically unattractive for the patient. Root-treated and resected tooth 21 had a fistula (Fig. 3a–c).

The existing denture is analysed intraorally and also on the basis of the casts. A first manual functional analysis already showed dysbalances and early contacts, which could also be verified by the wearing facets. The occlusal pattern was not stable.

Problems with Cast Transmission

The first examination and analysis of the cast shows that the occlusal plane does not correspond to the physiological conditions. With the so-called ‘hand articulation’, the anatomical fixed areas are marked. These include the sutura palatina mediana (palatal suture–skeletal midline), the area of the first molars (chewing centre) and the hamulus pterygoids (tuber

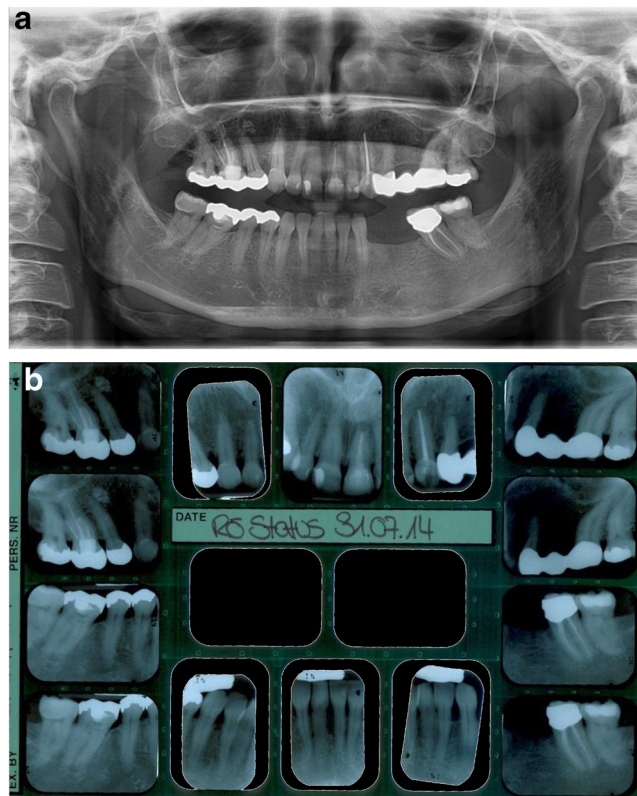


Fig. 2 a, b Initial situation. The x-ray shows the loss of teeth 34 and 35 in the mandible; root canal treatments on teeth 16, 21, 23 and 36; and numerous restorations

maxillae) in the upper jaw and the attachment of the frenulum in the lower jaw. Holding the two models together immediately leads to the recognition of a functional defect, since the dental and skeletal centres do not fit together.

Aetiologically, the situation can be interpreted as follows: the orthodontic treatment in childhood and the early removal of tooth 14 reduced the maxillary arch; thus, the crossbite on the right and the missing height (no support on the right) developed (Fig. 3c).

This is a functional compensation due to exogenous influences. The natural adaptation is usually completed at the age of about 15 years [2–5] (Fig. 4a,b).

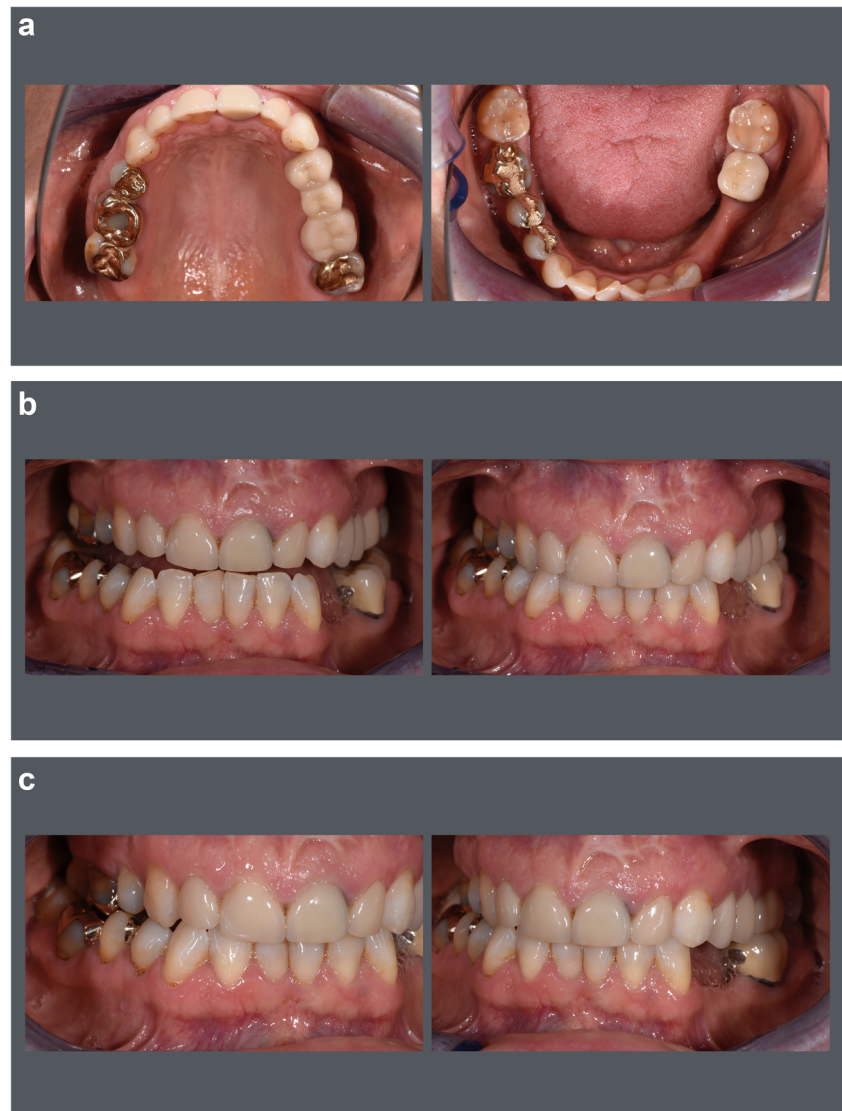The patient now tries to compensate these chewing functional disturbance factors and is thus forced into a physical malposition (scoliosis curvature to the left, skeletal centre shifted to the right)—as a result of a *descending chain*. The patient is neither in her correct skeletal nor in her correct muscular position.

The lower jaw is shifted to the right dorsocranial; thus, the head posture shifts towards the rear right (due to missing support). The muscular shortening on the right (hard, lacking elasticity) and the muscular reinforcement on the left are due to the stronger activity and due to the missing teeth 34–36.

Furthermore, the dental history shows how and why teeth were restored. During the fabrication of the old dental prosthesis, the models are usually transferred to the articulator on the basis of a face bow. The reference on the skull for the fabrication of the denture is usually the Frankfort horizontal or Camper's plane as arbitrary axis. However, the dental technician then lacks important information in relation to the actual head position. Among other things, this could be the reason for the misinterpreted occlusal plane. In addition, new transfer errors were probably subsumed at large intervals due to the step-by-step restoration over long time intervals and the occlusal chewing pattern was thus unphysiologically altered.

Although the occlusal plane was positioned well in the articulator, for example in relation to the Frankfort horizontal plane, the real situation reveals a completely different picture [6]. Working with skull-related instead of skull-specific references makes communication between dentist and dental technician more difficult. The situation from the mouth/skull is not identical with the laboratory articulator. In studies, among others by Xie et al. [7] and Ferrario et al. [8], scientists found that the connecting line from the lower edge of the ala of the nose to the midpoint of the tragus, i.e. the ala-tragus plane, is more exactly parallel to the occlusion plane than the frequently used Camper's or Frankfort plane (Fig. 5a,b). The ala-tragus plane can vary from patient to patient, in whom asymmetries are found. In order to reliably reproduce the occlusal plane, it is therefore necessary to capture it independently of the skeletal class [8–11].

Figs. 3 a–c The restoration at the beginning of the treatment



The answer to the question of the extent to which the occlusal plane of the denture deviates from the physiological situation results from a measurement for which a zero line serves as a reference. Zero lines are reliable and reproducible reference lines which are used, for example, in the software to evaluate various parameters. These include occlusal deviations within the dental arches and/or lateral deviations of the planes.

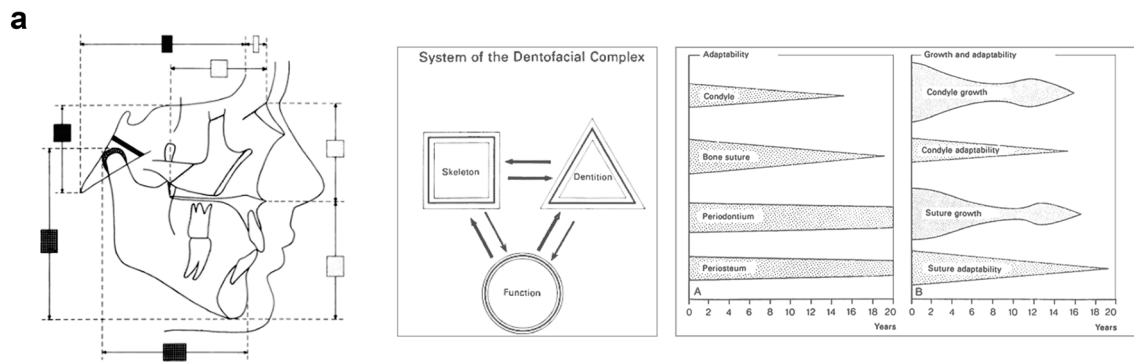
In the present case, these findings can now also be analysed and confirmed extraorally.

Identification of the Physiological Situation

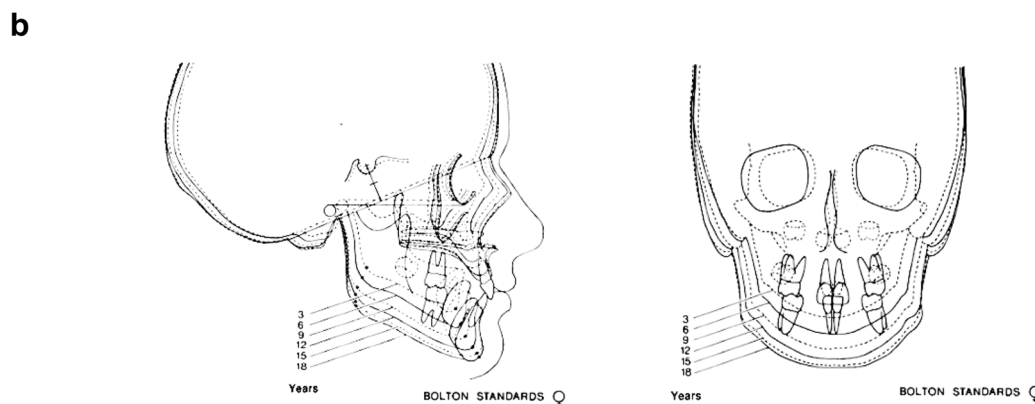
For this purpose, the patient positions herself in her natural head position by standing in front of a mirror. The natural head position (NHP) is the natural posture (without exogenous

influences) in which the patient is in balance and looks herself into the eyes in the mirror. In a 5-year study by Cooke [12], Peng and Cooke [13], Chan [5] and Sinobad and Postic [11], it was shown that a patient only varies his/her natural head position by 1° or 2° as soon as he/she looks himself/herself directly into the eyes when looking in a mirror whilst standing upright. The result is supported by a 15-year study by Peng and Cooke [13].

In the natural head position, the craniofacial growth, the positioning of the denture in the skull and the speaking distance are assessed (Fig. 6). Each person has a strong and a weak half of the face, a normal asymmetry that must be taken into account when creating dental restorations. In addition, orthodontic studies, such as by van der Linden [2–4], showed the reference of the first molar (chewing centre) in the orofacial system and the dependence on growth. When testing the speech motor skills, it can be seen that the patient pushes



Facial Growth and Facial Orthopedics Van der Linden



Van der Linden

Fig. 4 a, b Functional compensation due to exogenous influences

her head forwards when speaking (head projection) and backwards when biting. This analysis is done by the physiotherapist. According to Hergenroether [1], seven compensation points can be defined on the skeleton: from lateral for the forward head posture or backward posture, from frontal for the rotation (Fig 7a).

Based on the analysis, it is confirmed that the existing denture is insufficient in the vertical plane. For a new restoration, the vertical dimension of the occlusion (VDO) must be built up. An Aqualizer is used to balance (neutralise) the lower jaw position (Fig. 7a,b). This flexible occlusal aid consists of two cushions filled with liquids, which are connected and linked with each other after inter-occlusal placement. After insertion of the Aqualizer, the patient finds a comfortable, symptom-free position (most comfortable position (MCP)) and corrects the height independently (Fig. 7b).

After neutralisation with the Aqualizer, a front tooth jig at the correct height is made from a recording material. After processing the jig, a point-shaped central lower incisal contact point remains. The extension to the middle of the skull is marked on the jig. The anterior jig already normalises the head posture in the physiological region.

Now, the anatomical extraoral orientation points, the so-called 'landmarks', e.g. superior frenulum, inferior frenulum, ala-tragus, jaw angle and os zygomaticum, are analysed in relation to the tooth restoration in speech motor skills (Fig. 8). The situation is similar to the diagnostics of the teleradiograph, whereby no statements can be made about the musculature with the radiograph.

Mounting the Casts

To mount the casts, the support pin on the articulator is set to 0 (Fig. 9a,b). The physiological vertical dimension was developed together with the patient and should not be changed subsequently on the articulator.

The information for the positioning of the skull is transferred to the PlaneFinder® (Zirkonzahn, South Tyrol), and the natural head position is verified. The zero line is again the reference. The ala-tragus plane specifies according to which plane the new dental restoration must be created. An inclination of 9° on the right side and 7° on the left side is validated. The measuring angles (ala-

Fig. 5 **a** Head position in comparison with NHP and facebow (Frankfort and Camper's planes). **b** The same perspective as working basis for a dentist or dental technician

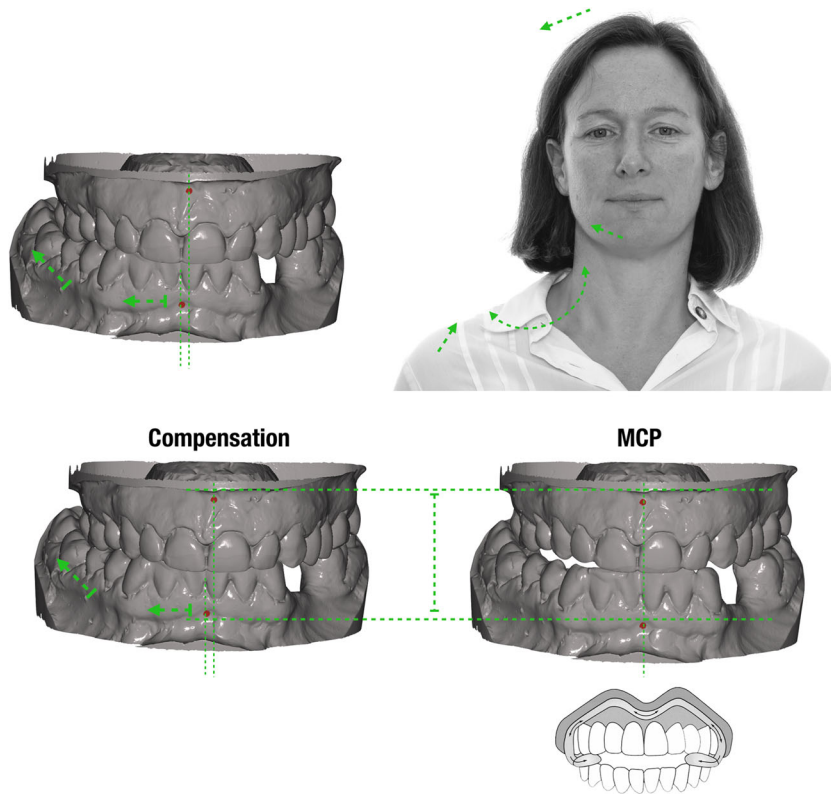
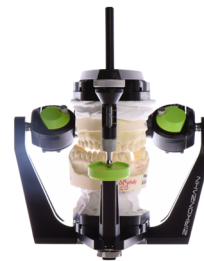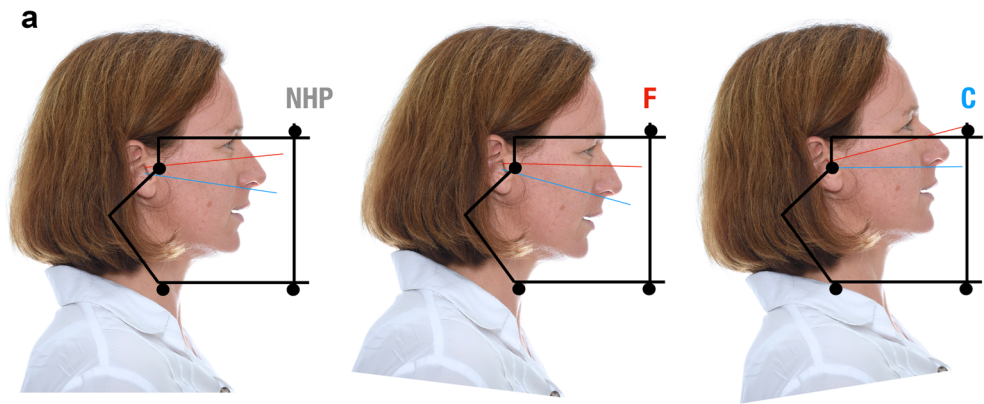
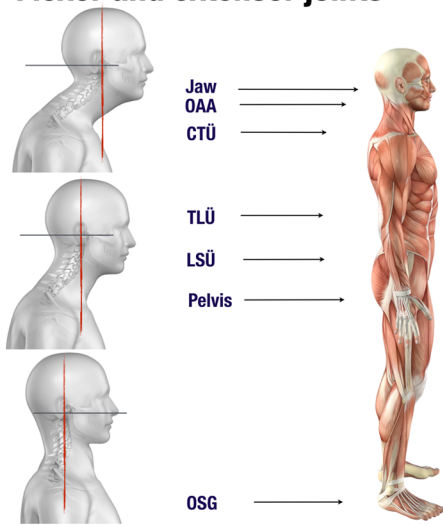


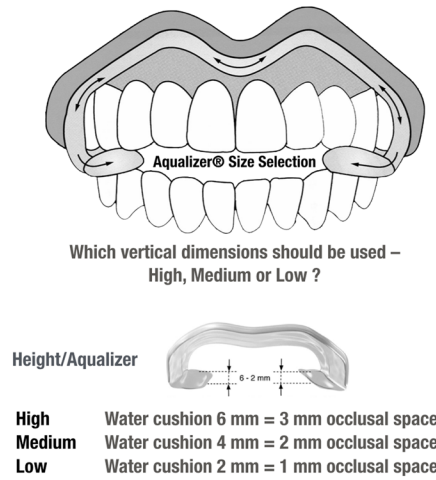
Fig. 6 With the model analysis you can compare, simulate and control the real posture of the patient respectively the malposition

a

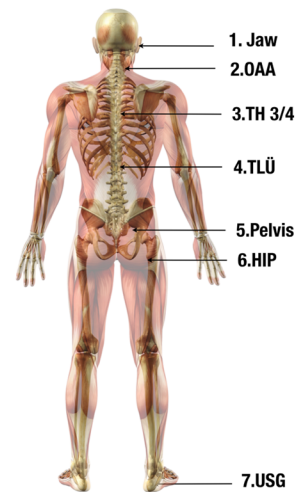
Flexor and extensor joints



Vertical dimension of occlusion



Rotation centers



b

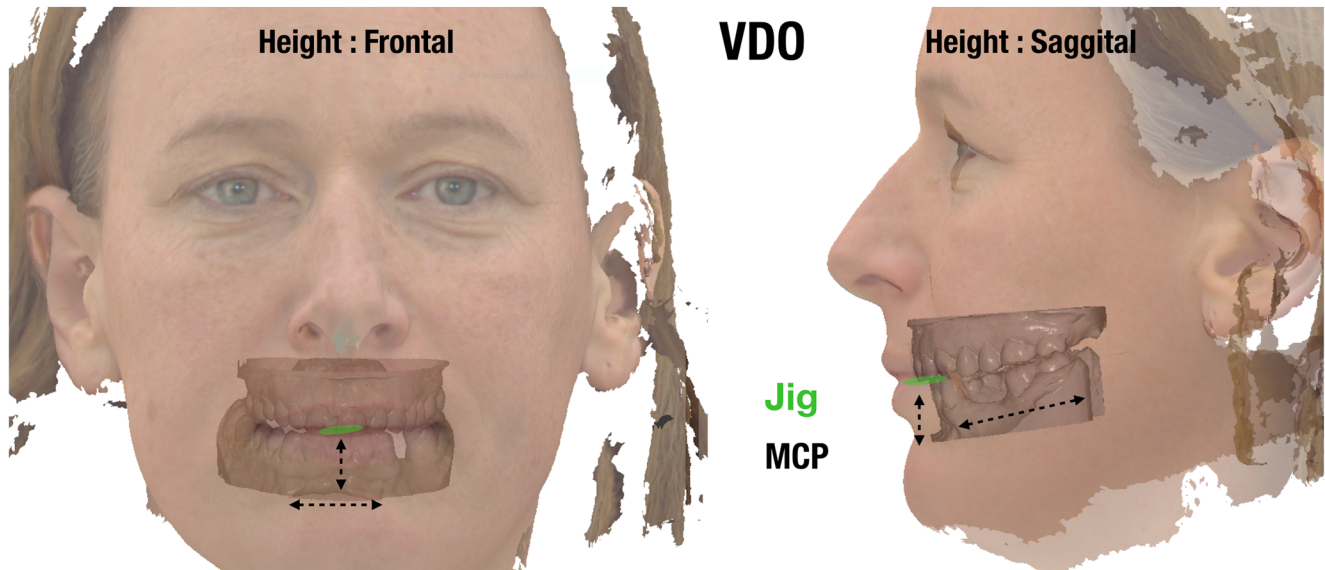


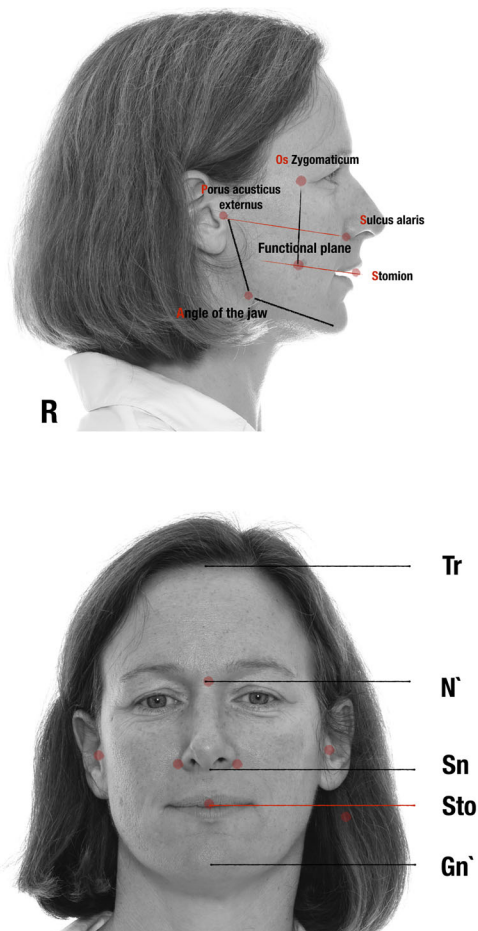
Fig. 7 **a** The vertical height will be influenced depending on the skeletal classification and the rotation center of the body. **b** Analysis of the most comfortable position

tragus angle) are equivalent to the worktable on the articulator. The situation is digitised and transferred into the Zirkonzahn.Scan software. Thus, the dental technician now has a 1:1 digital view of the physiological situation from the patient's mouth (Fig. 9e–d2). In the virtual articulator window of the additional Zirkonzahn.Modifier software (Zirkonzahn, South Tyrol), which has been developed in the meantime, the situation can be digitally verified and used as an exact basis for the tooth set-up and can also be returned to the analogue articulator via a positioning pattern (Fig. 9e; Fig. 10a–c) [1, 12, 14].

Production of a Functional Bite Splint

If such a finding is presented and a functional disorder has existed for a long time, it is advisable to create an adjusted splint in the lower jaw in order to determine the physiological centric relation exactly. This should already be produced in the correct VDO, which was determined by the registration technique with the jig, already defined in height (Fig. 11a,b).

The fabrication was then based on the information obtained during diagnostics and analysis.



Anatomical landmarks Sagittal plane

Anatomical landmarks Frontal plane

Trichion
Nasion
Subnasale
Stomion
Pogonion

Fig. 8 Position of the anatomical landmarks

Preprosthetic Pretreatment and Implantology

During the wearing period of the splint (material: Temp Premium Flexible Transpa, Zirkozahn, South Tyrol), accompanied by physiotherapy, the centric relation must be checked at regular intervals and adjusted if necessary. The patient's pains improved considerably in a very short time, with the result that the motivation to wear the splint also during the day was very high and compliance was optimal.

At this point, the overall planning was discussed and developed within the dentist team (orthopaedist, physiotherapist, dentist, dental technician) and together with the patient. In addition to the desire to optimise aesthetics and to adjust the perfect function, the patient expressed the desire to preserve individual teeth and to refrain from bridge connections.

Due to the changes in the vertical height and the three-dimensional correction of the planes, a complete rehabilitation was absolutely necessary for this patient case. Teeth 21 and 24, which were not worth preserving, were removed and replaced with implants. Implants were also placed in the existing gaps 25, 34 and 35 (all implants are SPI Element implants from the company Thommen Medical, Grenchen, Switzerland) (Fig. 12a,b).

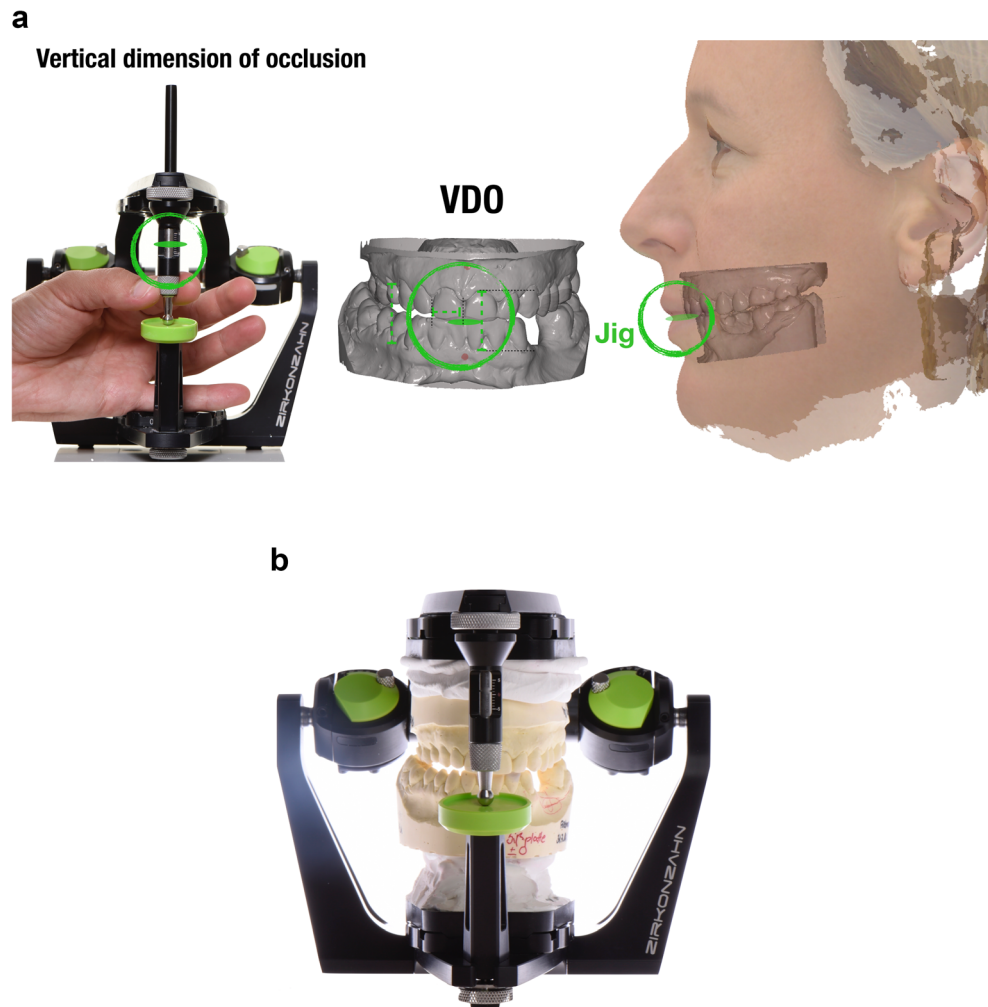
In region 21, a special technique was used to preserve the buccal lamella before the implantation. With the Tissue Master Concept (TMC, according to Dr. Stefan Neumeier) modified by the dentist, the fractured root canal was removed and the coronal part with a thickness of approx. 2 mm was *replanted* again as a root segment (Fig. 12b, c; Fig. 13a–d). It has been taken care that the root skin with the desmodontal fibres still adhering circularly to the root was preserved. Revascularisation prevents collapse of the bundle bone and, in particular, resorption of the buccal bone portion. After approx. 3 months of healing, the root segment can then be removed and the implant can be inserted immediately into the regenerated bone (Fig. 13a–d) [17, 18].

During the healing period, the mandibular splint continues to be worn and the centric relation is stabilised.

Therapeutic Transition Restoration

By capturing patient-individual information, the prosthetic, surgical and physiotherapeutic work team reached the intermediate goal of establishing the centric relation and inserting the implants.

Fig. 9 **a, b** The elaborated physiological height of the bite is determined in the PS1 Articulator (Zirkonzahn, South Tyrol). The support pin is set to 0 for this purpose. This height should not be changed any more. **c** Position_Software frontal. **d** Position_Software Sagittal. **e** Position_Scan_Software_Modifier Jaw_Positioner (**c-e** the reality was implemented to the digital world 1:1)



By registering the head posture, recording the facial proportions, the model analysis, the analysis of patient-specific movement data and the presentation of the mandibular position in unmanipulated centrics, it was possible to establish a stable occlusion with the splint.

After the healing-in of the implants, the old restorations in the maxilla could be removed and the natural occlusal plane could be reconstructed on the basis of the stable splint position.

In the upper jaw, the finished prosthesis is already being planned, and the lower jaw is initially being restored with therapeutic restorations (table tops made of milled composite). During the provisional phase, the body already adjusts to the physiological occlusion. A significant change is not only noticeable aesthetically. More importantly, the patient is now completely symptom-free. She already felt comfortable with the splint and indicated that she had the same balanced feeling with the temporaries in the upper jaw and the table tops in the lower jaw as with the splint. Speaking was also much more pleasant for her.

Planning and Implementation of the Final Restoration

A fixed denture on the teeth with single crowns (16–11, 22, 23, 26, 46, 37), veneers (43, 33) and partial ceramic crowns (17, 27, 38, 44, 45, 47) as well as screw-retained hybrid abutment crowns on the implants (21, 24, 25, 34, 35) are now planned.

Due to the reproducible and stable centric relation with the splint as well as the precise determination of the planes, the preparation of the teeth, the impression taking and the fabrication of the final denture can be carried out in the upper jaw—after removal of the old restorations and restoration of the teeth with adhesive build-up restorations. The technician knows the necessary information and anatomical landmarks both intraorally and extraorally.

A preparation key, which was manufactured exactly on the basis of the stable centric relation found (with correct VDO), serves for sequential preparation and sequential relining. This allows an optimal bite registration that corresponds in the vertical and horizontal directions to the stable splint position

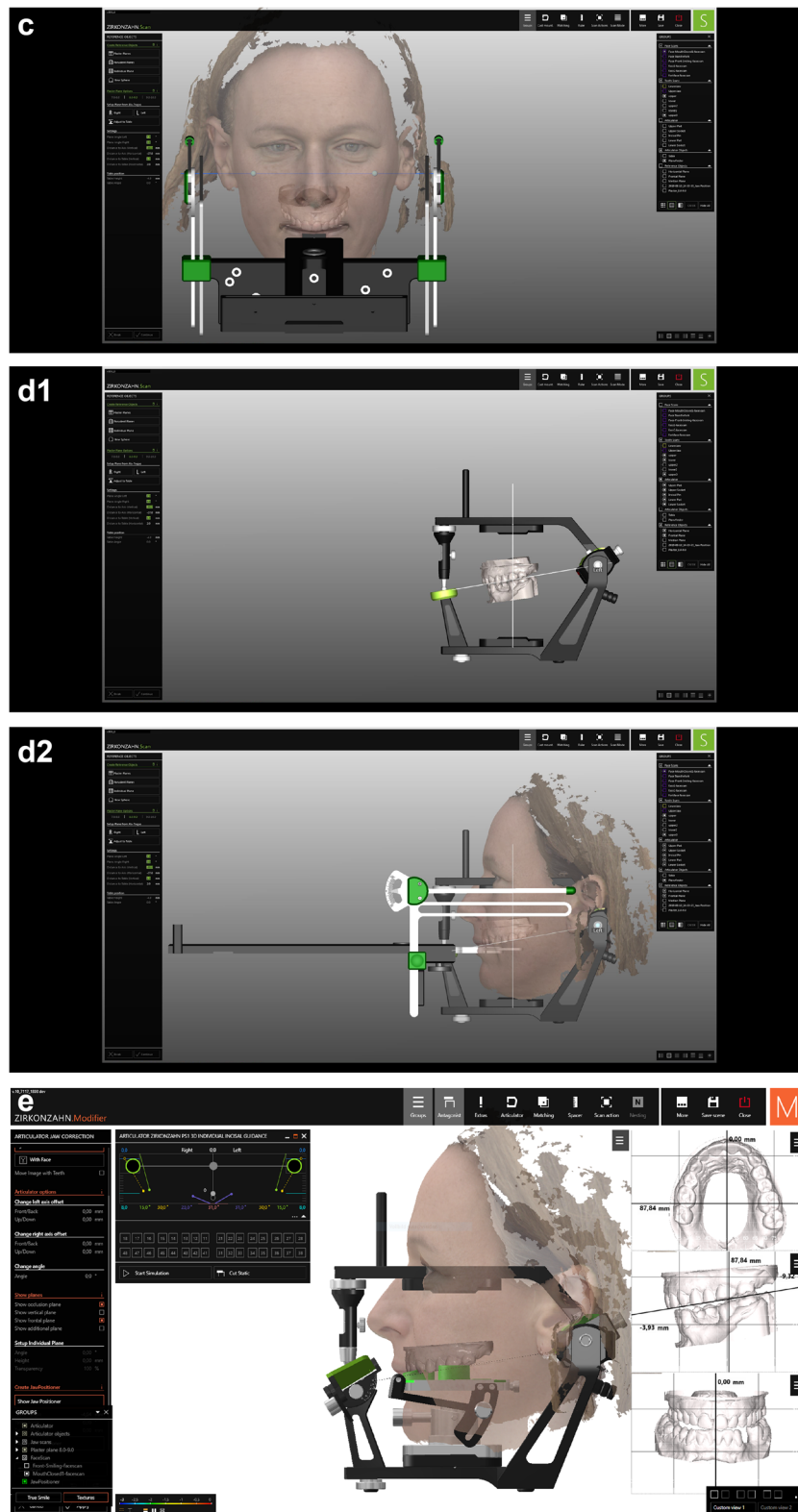


Fig. 9 c-e the reality was implemented to the digital world 1:1

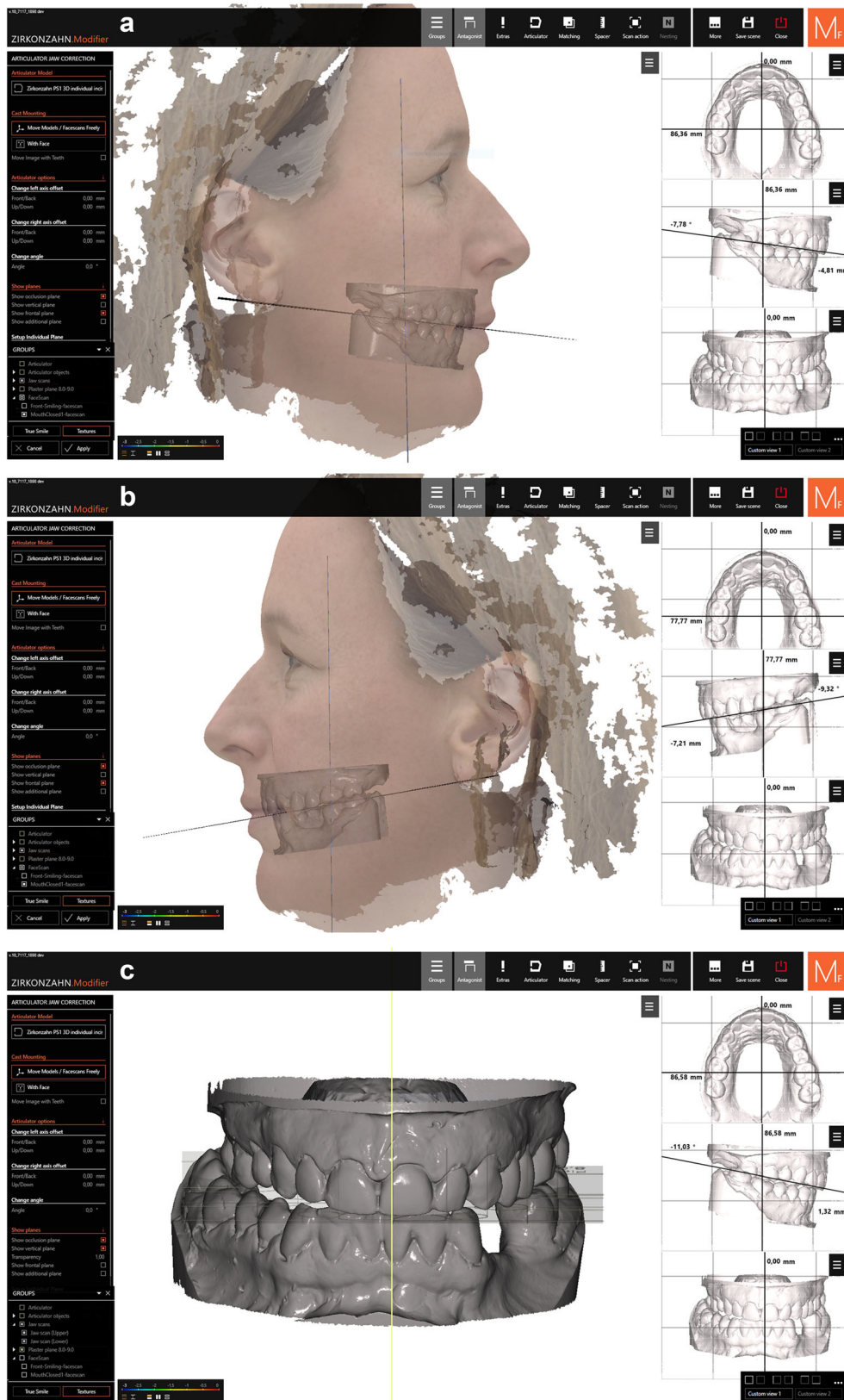


Fig. 10 a–c Analysis the anatomical plane (Ala Tragus) and skeletal midline

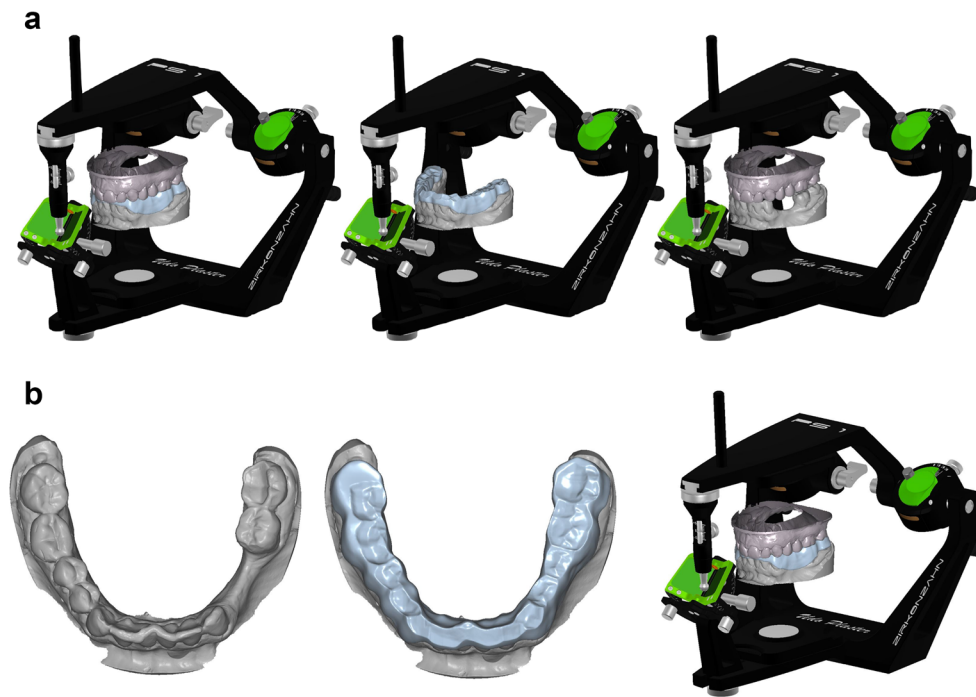


Fig. 11 Creating a splint or transfer plate digitally without changing the VDO

(physiological, non-manipulated centric relation of upper and lower jaws) (Fig. 14a–c).

In order to optimise the occlusal planes on the right and left and to transmit the vertical line exactly, table tops are fabricated in the lower jaw which compensate the occlusal differences and transfer the created stable splint position 1:1.

The table tops also serve to check the desired situation and determine whether the vertical plane is comfortable and functional for the patient in everyday life.

During the transition period, the patient verifies wearing comfort, hygiene, functional conditions and, of course, the aesthetics. Everything is to her satisfaction. Phonation is no longer disturbed. She visibly feels comfortable with the restoration and only wished for a slightly lighter tooth colour for the final restoration. She is painless and has no more tension in the neck area. This stable situation is the perfect time to firmly integrate the upper jaw restoration (Fig. 15).

Fabrication of the Final Restoration from a Dental Technical Point of View

The data pool with all patient-specific information is again the basis for the framework design for the maxillary restoration in the Zirkonzahn.Modellier software (Zirkonzahn, South Tyrol). For the areas where the teeth are to be restored with crowns (teeth 16–11, 22, 23 and 26), frameworks are milled out of Prettau® 2 zirconia (Zirkonzahn, South Tyrol), which are then veneered with feldspathic ceramics (Creation, Willi Geller Dental). Teeth

17 and 27 are fabricated with ceramic partial crowns from e.max Press (Ivoclar Vivadent, Schaan, Liechtenstein).

Implant 21 is screw-retained with an individual hybrid abutment made of zirconia (Prettau®, Zirkonzahn, South Tyrol) with a slightly subgingival buccal and epigingival palatal margin. This is connected to a titanium adhesive base which was bonded in the laboratory (Multilink hybrid abutment adhesive, Ivoclar Vivadent).

The abutment is then fitted with a crown, which is then bonded onto it. This technique is always necessary when the screw access cannot be placed in the invisible area for aesthetic reasons. A subgingival margin that is too pronounced must be avoided in order to prevent cement from remaining in the peri-implant gingiva area.

Hybrid abutment crowns made of Prettau® zirconia (Zirkonzahn, South Tyrol), which are also fixed on a titanium adhesive base (Thommen Medical, Grenchen, Switzerland), are fabricated and occlusally screw-retained on implants 24 and 25. It is important that the screw channels are lightly veneered from the inside to ensure an adhesive and thus permanently tight seal with composite.

After the digital design is completed, it is precisely milled in Prettau® zirconia (Zirkonzahn, South Tyrol) using the 5 + 1-axis simultaneous M5 milling unit. This zirconia material combines high flexural strength values (up to 1200 MPa) with good translucency properties and is therefore suitable for full-arch, aesthetic restorations.

Special colouring liquids (Colour Liquids Prettau® Aquarell) and intensive colours (Zirkonzahn, South Tyrol) are used to provide the restoration with a shade that is suitable for the patient.

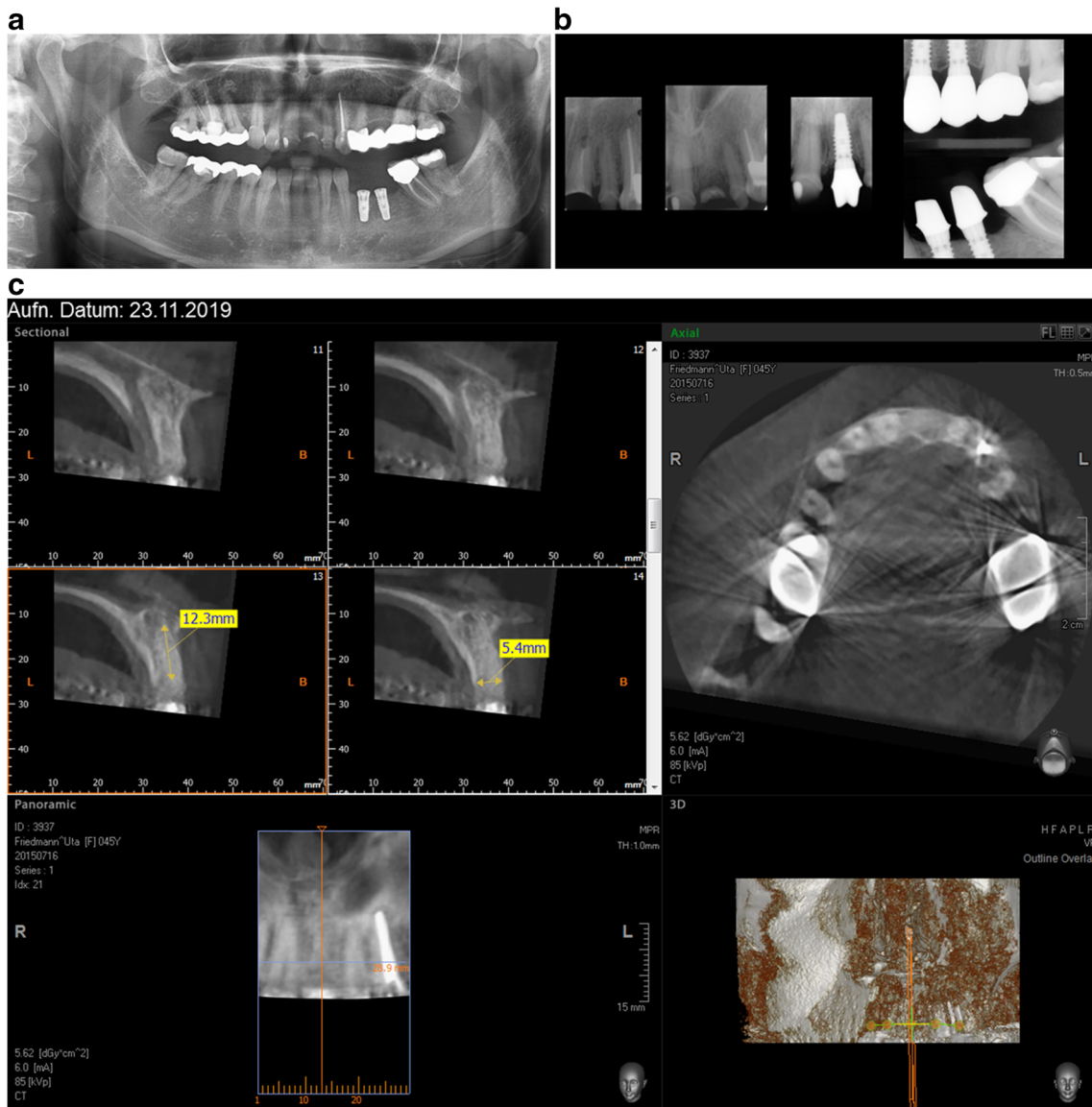

Fig. 12 a, b TMC by Dr. Stefan Neumeyer. Tooth 21 was not worth preserving and had to be removed gently. A piece of root was taken from the coronal part of the root and placed back in the alveolar socket

to preserve the bundle bone. The reattachment around the root disc avoided buccal bone collapse. c Cross Section after remodelling the bone with guided extrusion technique

After the restoration has been densely sintered in the Zirkonofen 700 Ultra-Vakuum sintering furnace (Zirkonzahn, South Tyrol) at 1600 °C, the result of the manual staining becomes apparent. Without post-processing, a good colouring base was achieved.

The aesthetically finalised maxillary restoration with the single crowns was veneered (Creation, Willi Geller Dental), whilst the occlusal and palatal areas in the posterior region were designed monolithically. After the ceramic layering, the restoration is prepared for colouring with ICE Zirkon 3D Stains by Enrico Steger (Zirkonzahn, South Tyrol) and for the final glaze firing.

After the final placement in the upper jaw and the adhesive fixation of the table tops in the lower jaw, a habituation phase of at least 3 months follows. Only after the patient has

confirmed that she still feels completely comfortable and free of complaints the final reconstruction of the lower jaw takes place, analogous to the procedure in the upper jaw.

In the mandible, teeth 46 and 37 are restored with zirconia crowns (Prettau®, Zirkonzahn, South Tyrol); teeth 38, 47, 44 and 45 with ceramic partial crowns (e.max Press, Ivoclar Vivadent, Schaan, Liechtenstein); and teeth 43 and 33 with ceramic veneer guides (e.max Press, Ivoclar Vivadent, Schaan, Liechtenstein).

Hybrid abutment crowns made of Prettau® (Zirkonzahn, South Tyrol), which are also fixed on a titanium adhesive base (Thommen Medical, Grenchen, Switzerland), are occlusally screw-retained on implants 34 and 35. As already described, it is crucial that the screw channels are lightly veneered from

Fig. 13 After a healing process of approximately 3 months, the alveolar bone was completely regenerated and the implant could be optimally positioned and immediately equipped with an individual healing cap to restore the soft tissue emergence

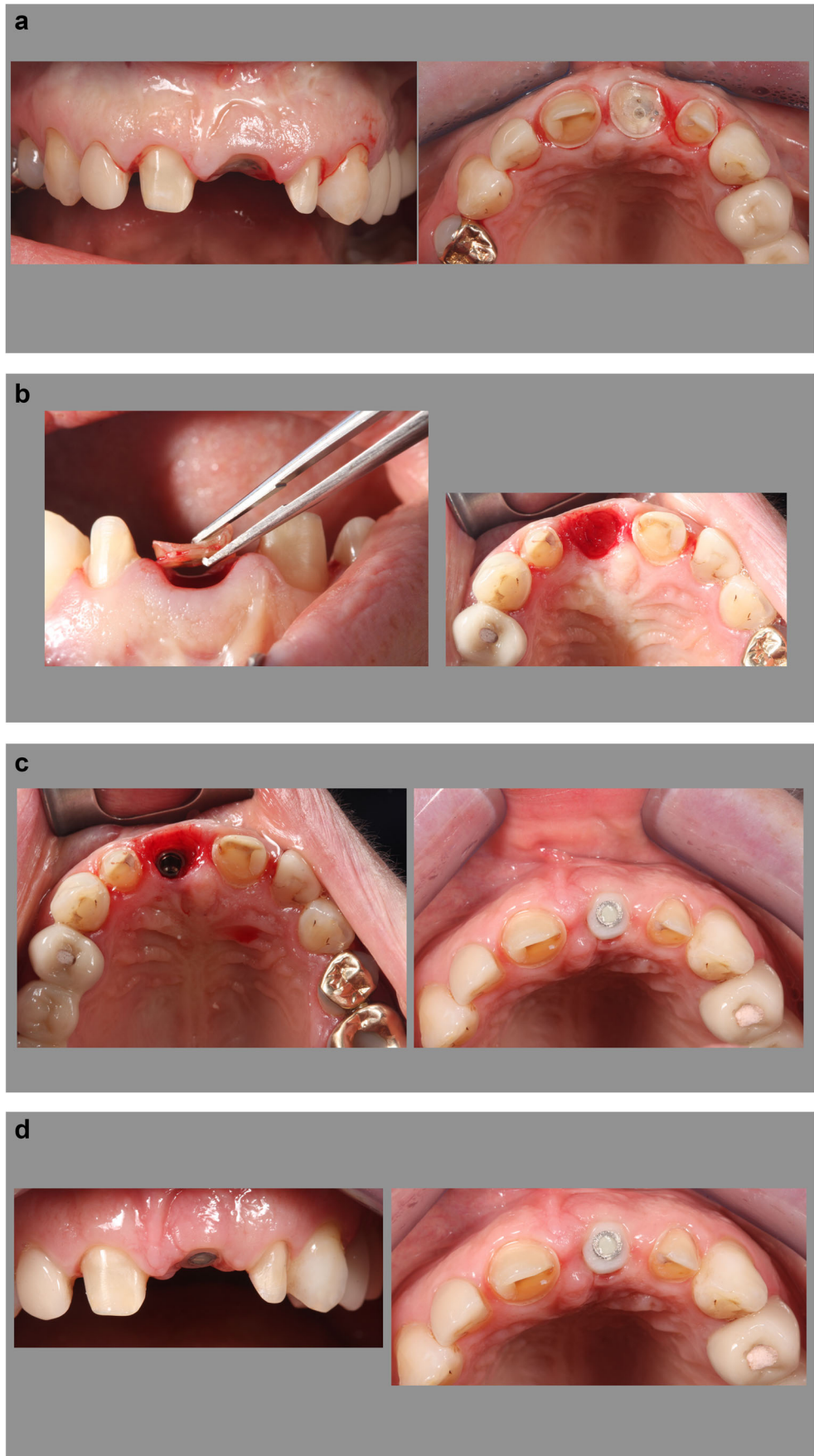
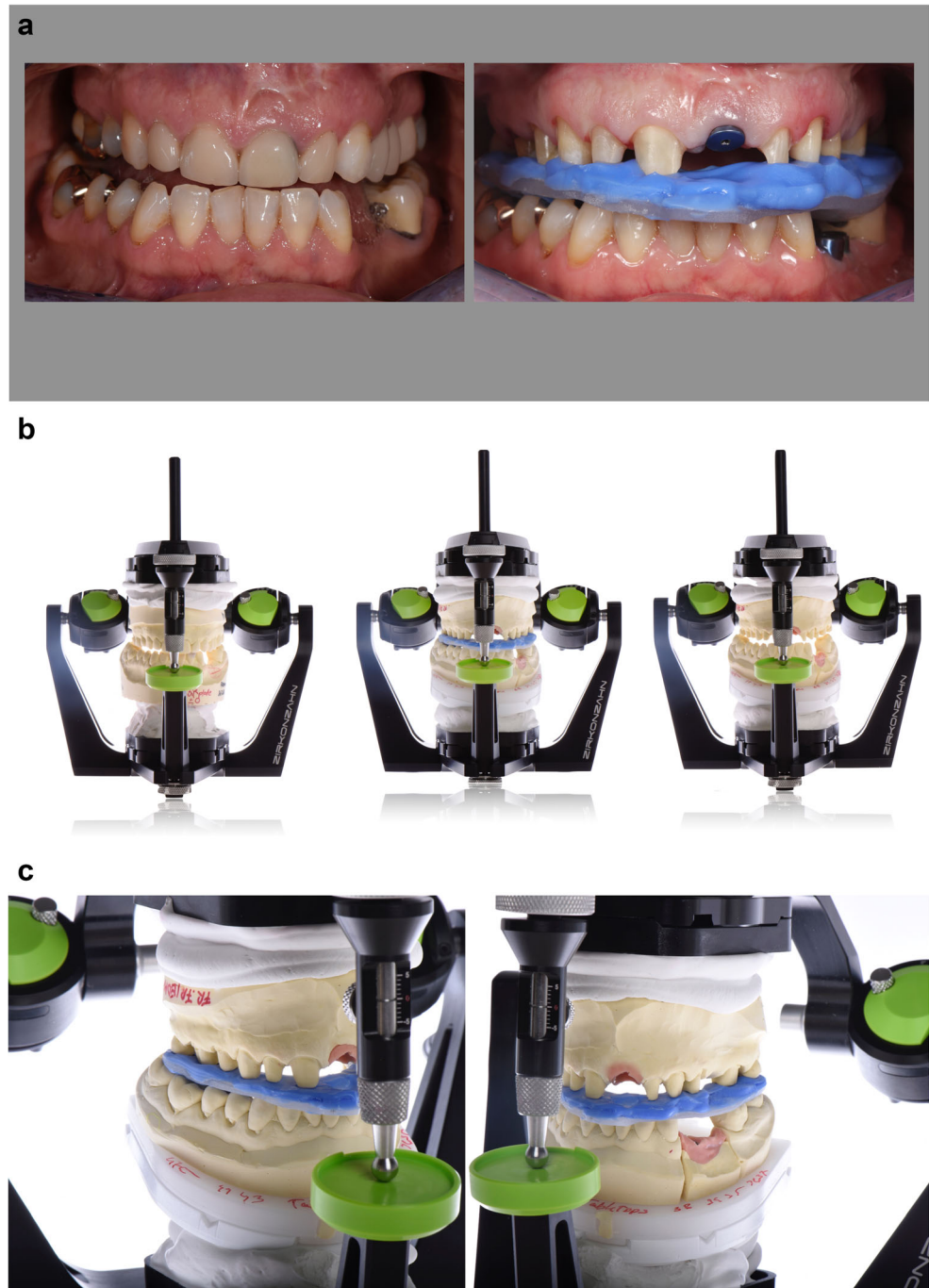


Fig. 14 a–c Splint position_T-plate_TÜR. Based on the stable centric relation, a preparation key was produced to secure the occlusion sequentially. With the help of this key, the master model was transferred and the dental technical work could begin



the inside to ensure an adhesive and thus permanently tight seal with composite (Fig. 15).

Summary

After the patient-specific reference planes were determined with the PlaneSystem®, it became apparent that several anatomical parameters and the old denture did not correspond to

the physiological conditions. By registering the head posture, recording anatomical landmarks, analysing the casts and the patient's individual movement data and displaying the lower jaw position in a non-manipulated centric, it was possible to achieve a first therapeutic success by creating a functional bite splint. This led to freedom of symptoms and thus formed the basis for further therapeutic steps, which included implant planning, surgical measures, the final restoration in the upper jaw and the intermediate therapeutic phase with table tops in

Fig. 15 Therapeutic transition restoration (table tops). After a healing phase of approx. 3 months, the alveolar bone was completely regenerated and the implant could be optimally positioned and immediately fitted with an individual healing cap to form the soft tissue emergence

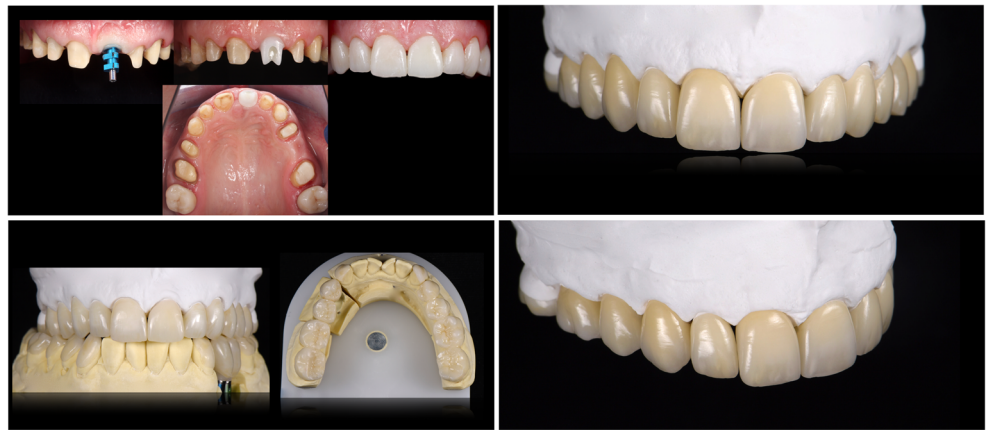
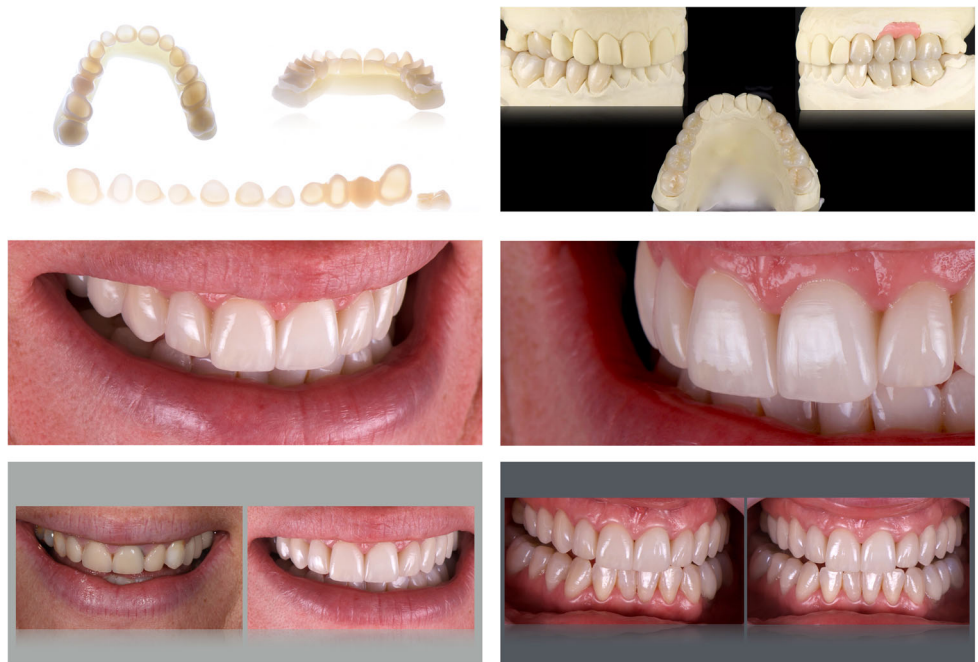
Fig. 16 Fabrication of the final restoration. Thanks to a holistic approach, targeted planning and close interdisciplinary cooperation, the restoration made of Prettau® provides the patient with optimum aesthetic and functional care and relieved her of her long-standing whole body pains



the lower jaw and finally resulted in the definitive reconstruction of the lower jaw.

Until now, 3.5 years after completion, the overall situation is stable, the patient is completely symptom-free and all restorations are fully intact (Fig. 16).

Conclusions

If the occlusion plane of a restoration does not correspond to the physiological conditions, this often leads to physical problems such as tension and headaches. This case presents, among other things, the collection of the patient-specific movement data and the determination of a non-manipulated centric, which, in the end, led to the patient becoming symptom-free. An important intermediate step was the production of two therapeutic prototypes.

Compliance with Ethical Standards

Conflict of Interest Dr. Marquardt declares no conflicts of interest.

MDT Plaster reports the following patents: Ihr EU-Patent 271 25 75, hier: italienischer Teil des Patents (50 2016 000 078 790), and Ihr EU-Patent 271 25 75, hier: 1. deutscher Teil des Patents (DE 50 2013 003 454.2); 2. italienischer Teil des Patents (50 2016 000 078 790); 3. österreichischer Teil des Patents (E 807 196).

Human and Animal Rights and Informed Consent This article does not contain any studies with human or animal subjects performed by any of the authors.

References

- Hergenroether R. CMD-Patient in der Physiotherapie. *Zahntech Mag.* 2015;18:260–7.
- van der Linden FPGM. Development of the human dentition, 1st edn. Quintessence, 2016.
- van der Linden FPGM. Orthodontics with fixed appliances, 6th edn. Quintessence, 1997.
- van der Linden FPGM. Facial growth and facial orthopedics. Quintessence, 1986.
- Chan CA. A review of the clinical significance of the occlusal plane: its variation and effect on head posture—“Optimizing the neuromuscular trajectory—a key to stabilizing the occlusal-cervical posture.”
- Hugger A, Türp JC, Pröschel P, Strub JR, Stüttgen U. Die Anwendung von Gesichtsbögen in der restaurativen Therapie und Funktionsdiagnostik – welches Evidenzniveau liegt vor? *Dtsch Zahnärztl Z.* 2001;56:671–5.
- Xie J, Zhao Y, Chao Y, Luo W. A cephalometric study on determining the orientation of occlusal plane. *Hua Xi Yi Ke Da Xue Xue Bao.* 1993;24:422–5 [Article in Japanese].
- Ferrario VF, Sforza V, Serrao G, Ciusa V. A direct in vivo measurement of the three-dimensional orientation of the occlusal plane and of the sagittal discrepancy of the jaws. *Clin Orthod Res.* 2000;3:15–22.
- Schöttl R, Plaster U. Modellübertragung und Kommunikation zwischen Zahnarzt und Zahntechniker. *Quintessenz Zahntech.* 2010;36:528–43.
- Schöttl R. Scharnierachse ade! *Myobyte.* 2008;2:7–14.
- Sinobad D, Postic SD. Roentgenraniometric indicators of the position of the occlusal plane in natural and artificial dentitions. *Eur J Prosthodont Restor Dent.* 1996;4:169–74.
- Cooke MS. Five-year reproducibility of natural head posture: a longitudinal study. *Am J Orthod Dentofac Orthop.* 1990;97:487–94.
- Peng L, Cooke MS. Fifteen-year reproducibility of natural head posture: a longitudinal study. *Am J Orthod Dentofac Orthop.* 1999;116:82–8.
- Marquardt S, Moser A. Funktionelle Ästhetische Rehabilitation – Die Übertragung der realen anatomischen Parameter in den Artikulator. *Quintessenz Zahntechnik.* 2014;40(11):1406–16.
- Fonseca M, Plaster U, Strauß M. PlaneSystem – Bestimmung der genauen Lage der Mitte und der individuellen Okklusionsebene im Verhältnis zur natürlichen Lage des Oberkiefers bei einem (zahnlosen) Implantatfall – Teil 1. *Quintessenz Zahntech.* 2015;41:282–96.
- Fonseca M, Plaster U, Strauß M. PlaneSystem – Bestimmung der genauen Lage der Mitte und der individuellen Okklusionsebene im Verhältnis zur natürlichen Lage des Oberkiefers bei einem (zahnlosen) Implantatfall – Teil 2. *Quintessenz Zahntech.* 2015;41:844–58.
- Neumeier S. The tissue master concept (TMC): innovations for alveolar ridge preservation. *Int J Esthet Dent.* 2017;12(2):246–57.
- Neumeier et al. Ein biologisches Behandlungskonzept für die Extraktionsalveole Die Replantation und Extrusion von Wurzelsegmenten Implantologie 2014;22(2):149–158.
- Plaster U, Marquardt S. Analyse und Transfer referenzierbarer individueller Patienteninformationen mit dem PlaneSystem®. *Quintessenz Zahntechnik.* 2019;45(7):908–21.
- Bennett NG. A contribution to the study of the movements of the mandible. *J Prosthet Dent.* 1908;8:41–54 (reprinted 1958).
- Gysi A. In: Partsch, Bruhn, Kantorowicz. *Handbuch der Zahnheilkunde Band III.* 1926.
- Kato T. A study on the reference planes and lines for dental practice. [Article in Japanese]. *Aichi Gakuin Daigaku Shigakkaishi.* 1990;28:1–19.
- Kordaß B. Kieferrelationsbestimmung – eine Herausforderung. *Quintessenz Zahntech.* 2011;37:1105.
- Lauritzen A. Atlas of occlusal analysis. HAH: Colorado Springs; 1974.
- McCollum BB, Evans RL. The gnathological concepts of Charles E. Stuart, Beverly B. McCollum and Harvey Stallard. *Georgetown Dent J.* 1970;36:12–20.
- McCollum BB, Stuart CE. A research report. Scientific: South Pasadena; 1955.
- Ogawa T, Koyano K, Suetsugu T. Characteristics of masticatory movement in relation to inclination of occlusal plane. *J Oral Rehabil.* 1997;24:652–7.
- Ogawa T, Koyano K, Suetsugu T. Correlation between inclination of occlusal plane and masticatory movement. *J Dent.* 1998;26:105–12.
- Ogawa T, Koyano K, Suetsugu T. The relationship between inclination of the occlusal plane and jaw closing path. *J Prosthet Dent.* 1996;76:576–780.
- Ogawa T, Koyano K, Umemoto G. Inclination of the occlusal plane and occlusal guidance as contributing factors in mastication. *J Dent.* 1998;26:641–7.
- Plaster U. Fotografische Übersicht der ästhetischen Gesichtsbogenanalyse. *Quintessenz Zahntech.* 2012;38:140–60.

32. Plaster U. Natürliche Asymmetrien und die patientenindividuelle Wiedergabe der Okklusionsebene ohne traditionellen Transferbogen. *Quintessenz Zahntech.* 2013;39:1266–80.
33. Plaster U. Das Plane-System – vom analogen Gips- zum digitalen CAD-Modell. *Quintessenz Zahntech.* 2014;40:570–86.
34. Posselt U. *Physiology of occlusion and rehabilitation.* 2nd ed. Oxford: Blackwell; 1968.
35. Plaster, Udo Transfer of the patient's oral situation to the articulator and synchronizing the articulated models. Part 1, 2: occlusal plane and jaw relation—the analysis and transfer of information. *J Craniomand Func* 11 (2019), No. 2 (22.05.2019).
36. Agarwal G, Thomas R, Mehta D. Postextraction maintenance of the alveolar ridge: rationale and review. *Compend Contin Educ Dent.* 2012;33(5):320–4 326; quiz 327, 336.
37. Horowitz R, Holtzclaw D, Rosen PS. A review on alveolar ridge preservation following tooth extraction. *J Evid Based Dent Pract.* 2012 Sep;12(3 Suppl):149–60. [https://doi.org/10.1016/S1532-3382\(12\)70029-5](https://doi.org/10.1016/S1532-3382(12)70029-5).

Publisher's Note Springer Nature remains neutral with regard to jurisdictional claims in published maps and institutional affiliations.